

Patient-Reported Outcomes After Arthroscopic Shoulder Surgery With Interscalene Brachial Plexus Nerve Block Using Liposomal Bupivacaine: A Prospective Observational Study

ELIZABETH FORD, BA

LEAD ORTHOPEDIC RESEARCH COORDINATOR

LOURDES MEDICAL ASSOCIATES

3RD YEAR MEDICAL STUDENT

ROWAN UNIVERSITY SCHOOL OF OSTEOPATHIC MEDICINE
STRATFORD, NEW JERSEY

SUNDEEP SAINI, DO

DOCTOR OF OSTEOPATHIC MEDICINE

ROWAN UNIVERSITY SCHOOL OF OSTEOPATHIC MEDICINE
STRATFORD, NEW JERSEY

PATRICK SZUKICS, DO

DOCTOR OF OSTEOPATHIC MEDICINE

ROWAN UNIVERSITY SCHOOL OF OSTEOPATHIC MEDICINE
STRATFORD, NEW JERSEY

ANDREW A. ASSIAMAH, MD

DOCTOR OF MEDICINE

LOURDES MEDICAL CENTER OF BURLINGTON COUNTY
WILLINGBORO, NEW JERSEY

SEAN McMILLAN, DO, FAOAO

CHIEF OF ORTHOPEDICS

LOURDES MEDICAL ASSOCIATES

BURLINGTON, NEW JERSEY

ASSOCIATE CLINICAL PROFESSOR OF SURGERY

ROWAN UNIVERSITY SCHOOL OF OSTEOPATHIC MEDICINE
STRATFORD, NEW JERSEY

ABSTRACT

Background: Interscalene brachial plexus nerve blocks (ISBPNBs) are commonly used to mitigate postsurgical pain after shoulder surgery.

Materials and Methods: We performed a prospective observational study in 57 consecutive adult patients undergoing arthroscopic shoulder surgery with an ultrasound-guided ISBPNB using liposomal bupivacaine (LB; 133mg/10ml) mixed with 0.5% bupivacaine (10ml). All patients received prescriptions for 1000mg of oral acetaminophen and 10 5mg oxycodone tablets upon discharge.

Results: Post-discharge telephone surveys revealed that mean (standard deviation [SD]) patient-reported motor and sensory recovery times after surgery were 26.8 (3.2) and 34.0 (3.6) hours, respectively. The average (SD) visual analog scale pain score was 5.1 (3.1) at day two post-surgery. The estimated opioid utilization rate at day seven post-surgery was 21% of the prescribed opioid tablets.

Conclusions: Our real-world observational findings suggest that multimodal postsurgical pain control using single-shot, ultrasound-guided ISBPNB with LB and postsurgical acetaminophen provides favorable pain control and limited need for postsurgical opioid rescue for seven days after shoulder surgery.

INTRODUCTION

The opioid epidemic is familiar among all healthcare providers in almost all specialties, but it is especially familiar to orthopedic surgeons. In 2016, orthopedic surgeons were the third-leading prescribers of opioids, undeniably contributing to the issue of opioid addiction.¹ A study in 100 patients undergoing shoulder surgery found that patients were prescribed an average of 55 opioid tablets for postsurgical analgesia, of which an average of 20 were left unused; these unused tablets were proposed to be a potential source of diversion and abuse.² With increased pressure and legislation placed upon healthcare providers to reduce opioid prescriptions, orthopedic surgeons are seeking effective methods to limit the number of opioids consumed by their patients for postsurgical pain control.

Interscalene brachial plexus nerve blocks (ISBPNBs) have been commonly used to mitigate immediate postsurgical pain in patients undergoing arthroscopic shoulder surgery. Historically, the aqueous formulation of bupivacaine HCl has been a useful option for ISBPNBs. It has been shown to help reduce pain for the first 12 to 24 hours of postsurgical time. Continuous catheter-based

ISBPNBs have also been shown to be effective for prolonged postsurgical analgesia.³

Liposomal bupivacaine (LB; EXPAR-EL[®] [bupivacaine liposome injectable suspension]; Pacira Biosciences, Inc., Parsippany, New Jersey), a long-acting formulation of the local anesthetic bupivacaine comprising multivesicular liposomes that contain numerous nonconcentric internal aqueous chambers of bupivacaine (13.3mg/mL), is approved for use as an ISBPNB.⁴ The plasma bupivacaine pharmacokinetic profile after administering ISBPNB with 133mg of LB in patients undergoing shoulder surgery includes an early peak at six hours and peak concentrations at 48 hours, consistent with an extended release of bupivacaine.⁵ In this observational study, we investigated postsurgical pain scores and opioid use in adult patients undergoing arthroscopic shoulder surgery with an ultrasound-guided ISBPNB using a mixture of LB and bupivacaine HCl.

MATERIALS AND METHODS

This study was a prospective observational study examining consecutive adult patients who underwent planned arthroscopic shoulder surgery. Patient

demographics and procedural details were collected perioperatively, and all data were deidentified. Patients aged ≥ 18 years who were able to receive an ISBPNB and provide informed consent were included. Patients who were previously on opioid medications prior to surgery were not excluded; however, they were asked to report opioid consumption above their baseline regimen of medications.

All patients received an ultrasound-guided ISBPNB using 10ml (133mg) of LB mixed with 10ml of 0.5% bupivacaine. After the ISBPNB, patients underwent their indicated shoulder arthroscopies. All procedures were performed on an outpatient basis under general anesthesia in the lateral decubitus position by a single attending surgeon. Upon discharge, patients received a prescription for rescue medication for mild to moderate pain (oral acetaminophen 1000mg every six hours, as needed). All patients also received a prescription for 10 5mg oxycodone tablets, indicated for severe pain. Patients then underwent respective standard of care rehabilitation protocols. A telephone survey was conducted to record postsurgical pain scores (using a 10cm visual analog scale [VAS]), opioid consumption, and estimated return in sensory and motor function at 24 and 72 hours. Pain

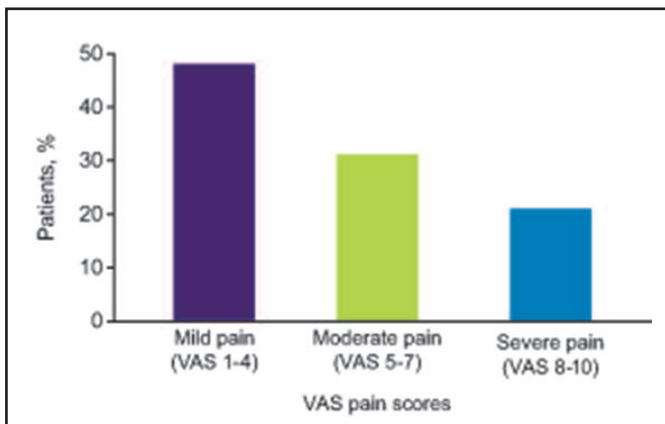


Figure 1a. After receiving an interscalene brachial plexus nerve block with liposomal bupivacaine before primary shoulder arthroscopy, patients reported postsurgical pain scores two days after surgery using VAS. Pain scores were categorized as mild (VAS 1-4), moderate (VAS 5-7), or severe (VAS 8-10).

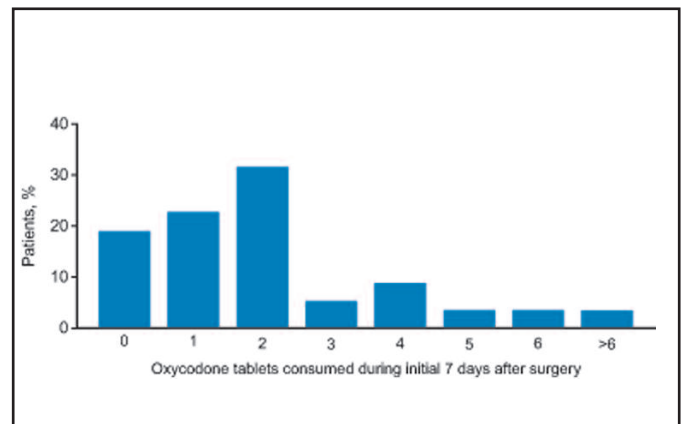


Figure 1b. The percentage of patients with a corresponding number of 5mg oxycodone tablets consumed during the initial seven days after surgery.

scores were categorized as mild (VAS 1-4), moderate (VAS 5-7), or severe (VAS 8-10). On day seven of the post-surgical course, the total numbers of remaining opioid tablets and consumed opioid tablets were recorded. All opioids were reported as morphine-equivalent doses (MED).

RESULTS

A total of 57 patients were included in this study. Mean (standard deviation [SD]) age of patients was 44.5 (12.9) years old, and 51% were male. Types of shoulder surgeries included rotator cuff repair (60%), labral repair (21%), biceps tenodesis (9%), distal clavicle excision (7%), and capsular release (3%). Patients reported motor and sensory recovery at a mean (SD) of 26.8 (3.2) and 34.0 (3.6) hours, respectively. The average (SD) postsurgical VAS pain score on day 2 was 5.1 (3.1), and 47% of patients reported mild pain (or VAS pain score of 1-4; Fig. 1a). Overall, patients consumed an average (SD) MED of 11.8mg, equating to 2.12 (2.05) opioid tablets per person. The approximate opioid utilization rate was 21% (120/570 opioid tablets), and 19% of patients did not consume any opioid tablets post-surgically (Fig. 1b).

DISCUSSION

The use of opioids for postsurgical pain control after shoulder arthroscopy is a widely accepted practice because of the known pain associated with these procedures. Previous literature suggests that approximately 35 opioid pills per patient are typically consumed for postsurgical analgesia after arthroscopic shoulder surgery.² The use of LB for ultrasound-guided, single-shot ISBPNB offers an opioid-minimizing alternative for analgesia after arthroscopic shoulder surgery.

Traditional ISBPNBs provide an average of eight to 24 hours of analgesic effect.^{3,6,7} Once this block wears off, patients have reported a “rush” of pain. To preemptively manage this pain, a traditional postsurgical protocol suggested that patients begin taking opioid medications before the onset of pain.

The results of our study demonstrate that ISBPNB with LB has a longer-acting effect on sensory and motor blockades. Furthermore, pharmacokinetic studies of LB have observed bupivacaine HCl concentrations in plasma up to 96 hours after surgery, depending on the dose utilized.⁸⁻¹⁰ The lingering effect of LB could enable a gradual “let-down” of the ISBPNB, which is counter to the typical heightened sensation of pain seen in the initial 72-hour period after traditional bupivacaine ISBPNBs. This gradual letdown enables the patient to become aware of the pain and initiate a multimodal approach to control pain and discomfort using opioid-minimizing approaches, such as acetaminophen or ice.

Educating the patient and their family members before and after surgery on the expected effects of the ultrasound-guided ISBPNB with LB may help minimize opioid consumption. Explaining when the ISBPNB is likely to wear off and what type of pain can be expected during the first 72 hours after surgery was anecdotally reported by patients to be very effective. Likewise, patients should be educated on the optimal timing for acetaminophen initiation and the role of opioids in pain management. Finally, informing patients that motor and sensory blockades last longer than traditional bupivacaine blocks may help reduce a sense of panic during the initial postsurgical period.

A limitation of this study is the observational nature of data collection and the lack of a comparator group. However, these real-world, clinical experience data demonstrate that the use of LB for single-shot ISBPNB in patients undergoing arthroscopic shoulder surgery, combined with postsurgical acetaminophen, limits the requirement for opioid rescue for seven days after surgery. Another limitation is that the procedural efficacy of ultrasound-guided ISBPNB with LB is affected by the skill and comfort level of the anesthesiologist, as LB remains concentrated at the injection site with little to no dissemination around the brachial plexus compared with standard bupivacaine. This effect is due to the multivesicular formulation of LB and requires precise and careful LB administration to perform an effective block. This may explain some of the variations in patient-reported postsurgical pain scores.

CONCLUSION

In conclusion, this study, which examined a decreased opioid consumption rate during the first seven days after shoulder arthroscopy, shows how postsurgical pain can be mitigated while reducing opioid prescriptions within the orthopedic community. Careful administration of and patient education on ISBPNB with LB is strongly suggested to obtain maximal benefit. Future controlled studies comparing traditional ultrasound-guided, single-shot bupivacaine ISBPNBs and ISBPNB with LB are warranted to better understand the potential for decreasing opioid requirements for shoulder surgery. **STI**

AUTHORS' DISCLOSURES

Dr. Mc Millan is a paid consultant for Pacira Biosciences, Inc.; however, neither funding nor compensation was exchanged for the preparation of this research or manuscript.

All other authors have no conflicts of interest to disclose.

ACKNOWLEDGMENTS

Editorial assistance was supported by Pacira Biosciences, Inc., Nathan Rodeberg, PhD, and Jenna Lewis, MA, MedThink SciCom, Inc.

REFERENCES

1. Volkow ND, McLellan TA, Cotto JH, et al. Characteristics of opioid prescriptions in 2009. *JAMA* 2011;305(13):1299-301.
2. Kumar K, Gulotta LV, Dines JS, et al. Unused opioid pills after outpatient shoulder surgeries given current perioperative prescribing habits. *Am J Sports Med* 2017;45(3): 636-41.
3. Vorobeichik L, Brull R, Bowry R, et al. Should continuous rather than single-injection interscalene block be routinely offered for major shoulder surgery? A meta-analysis of the analgesic and side-effects profiles. *Br J Anaesth* 2018;120(4):679-92.
4. Exparel [package insert]. San Diego, CA: Pacira Biosciences, Inc 2018.
5. Patel M, Gadsden J, Nedeljkovic SS, et al. Brachial plexus block with liposomal bupivacaine for shoulder surgery improves analgesia and reduces opioid consumption: results

FORD/SAINI/SZUKICS/ASSIAMAH/MCMILLAN

from a multicenter, randomized, double-blind, controlled trial. *Pain Med* 2019 [Epub ahead of print].

6. Brattwall M, Jildenstal P, Warren Stomberg M, et al. Upper extremity nerve block: how can benefit, duration, and safety be improved? An update. *F1000Res* 2016; 5:907.

7. Vandepitte C, Kuroda M, Witvrouw R, et al. Addition of liposome bupivacaine to bupivacaine HCl versus bupivacaine HCl

alone for interscalene brachial plexus block in patients having major shoulder surgery. *Reg Anesth Pain Med* 2017; 42(3):334–41.

8. Gadsden J, Long WJ. Time to analgesia onset and pharmacokinetics after separate and combined administration of liposome bupivacaine and bupivacaine HCl: considerations for clinicians. *Open Orthop J* 2016; 10:94–104.

9. Hu D, Onel E, Singla N, et al. Pharmaco-

kinetic profile of liposome bupivacaine injection following a single administration at the surgical site. *Clin Drug Investig* 2013; 33(2): 109–15.

10. Bramlett K, Onel E, Viscusi ER, et al. A randomized, double-blind, dose-ranging study comparing wound infiltration of DepoFoam bupivacaine, an extended-release liposomal bupivacaine, to bupivacaine HCl for postsurgical analgesia in total knee arthroplasty. *Knee* 2012;19(5):530–6.